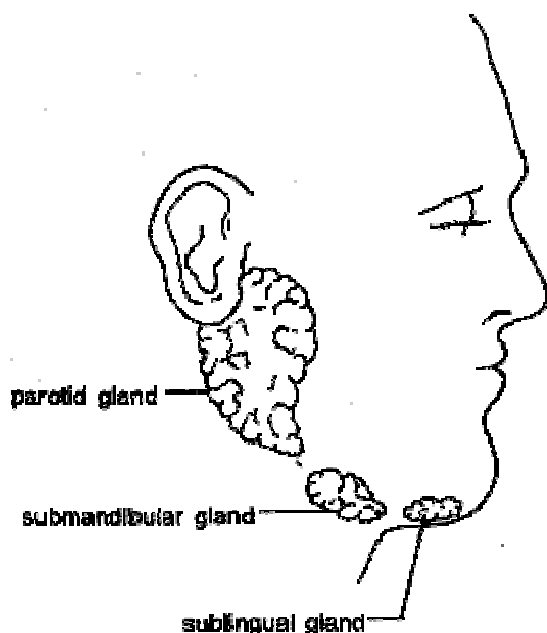


Salivary glands

Where are salivary glands?

The glands are located in and around the mouth and throat. The major salivary glands are called the parotid, submandibular and sublingual glands. They all secrete saliva into the mouth: the parotid through ducts near the upper teeth, submandibular into the front portion under the tongue, and the sublingual through multiple ducts in the floor of the mouth.

In addition to these glands, there are hundreds of tiny glands called minor salivary glands located in the lips, inner cheek area (buccal mucosa) and extensively in other linings of the mouth and throat. Salivary glands produce the saliva used to moisten your mouth, initiate digestion, and help protect teeth from decay.



Location of salivary glands

What causes abnormal glands?

Abnormalities of the salivary glands which cause clinical symptoms can be grouped as follows:

Obstruction

Obstruction to the flow of saliva most commonly occurs in the parotid and submandibular glands, usually due to stone formation. Symptoms typically occur when eating. Saliva production is initiated, but cannot exit the ductal system, leading to swelling of the involved gland and significant pain, sometimes with an infection.

Inflammation

If stones are not totally obstructive, the major glands will swell during eating and then gradually subside after eating, only to enlarge again at the next meal. Infection often develops in the abnormally pooled saliva, leading to more severe pain and swelling in the glands. If untreated long enough, the glands may become abscessed.

In some individuals the duct system of the major salivary glands may be abnormal. These ducts can develop small constrictions which decrease salivary flow, leading to infection and obstructive symptoms.

Infection

The most common salivary gland infection is mumps, which involves the parotid glands. While this is most common in children, it can occur in adults. However, if an adult has swelling in the area of the parotid gland on one side, it is more likely due to an obstruction or a tumour.

Infections occurring because of ductal obstruction or sluggish flow of saliva have already been mentioned. Secondary infection of salivary glands from adjacent lymph nodes also occurs. These lymph nodes are the glands in the upper neck which often become tender during a common sore throat. Many of these lymph nodes are actually located on, within, and deep in the substance of the parotid gland, near the submandibular glands. When these lymph nodes enlarge through infection, this is noticed by the patient as a red, painful swelling in the area of the parotid or submandibular glands. Lymph nodes also enlarge due to tumours and inflammation.

Tumours

Primary benign and malignant salivary gland tumours usually show up as painless enlargements of these glands. Tumours rarely involve more than one gland and are detected as a growth in the parotid, submandibular area, on the palate, floor of mouth, cheeks, or lips. These enlargements should be checked by an otolaryngologist - head and neck surgeon.

Malignant tumours of the major salivary glands can grow quickly, are painful, and can cause loss of movement of part or all of the affected side of the face. These symptoms should be immediately investigated.

Other

Salivary gland enlargement is also seen in autoimmune diseases, which cause significant inflammation. Patients often have a dry mouth or dry eyes. This may occur with other systemic diseases such as rheumatoid arthritis. Diabetes may cause enlargement of the salivary glands, especially the parotid glands. Salivary gland swelling (usually on both sides) is also seen in alcoholics.

How does your doctor make the diagnosis?

The diagnosis of salivary gland disease depends upon a careful history, a physical examination, and laboratory tests. If an obstruction of the major salivary glands is suspected, it may be necessary to anesthetize the opening of the salivary ducts in the mouth, and to probe, and dilate the duct to help an obstructive stone pass. Prior to such instrumentation, dental x-rays may show the location of calcified stones.

If a mass is found in the salivary gland, it is helpful to obtain an x-ray called a CT scan. CT scans will show whether the mass is an actual part of a salivary gland, or an associated lymph node.

In many cases a fine needle aspiration biopsy in the doctor's office is helpful. The accuracy of this test is approximately 80% to 90%. An open biopsy, where a skin incision is made and a small sample of the gland removed, is not usually recommended in the office. This is an incisional biopsy and because of the possibility of injury to underlying nerves within the parotid gland may need to be done in the operating room.

Treatment of salivary gland disease

Treatment of salivary diseases is broadly classified into two categories: medical and surgical. Selection of treatment depends upon the nature of the problem. If it is due to systemic diseases (diseases that involve the whole body, not one isolated area), then the underlying problem process must be treated. This may require consultation with other specialists. If the disease process relates to salivary gland obstruction and subsequent infection, antibiotics are used. Sometimes instrumentation of the ducts will be needed.

If a mass has developed within the salivary gland, removal of the mass may be required. Most masses in the parotid gland area are benign. When surgery is necessary, great care must be taken to avoid damage to the facial nerve which lies within this gland. When malignant masses are present in the parotid gland, it may be possible to surgically remove these masses and preserve most of the facial nerve. Radiation treatment will often be recommended after surgery. This is typically administered four to six weeks after the surgical procedure to allow adequate healing before irradiation.

The same general principles apply to masses in the submandibular area or in the minor salivary glands within the mouth and upper throat. Benign diseases are best treated by surgery alone, whereas malignant diseases may require surgery and postoperative irradiation. If the mass in the vicinity of a salivary gland is a lymph node which has become enlarged due to cancer from another site, then obviously a different treatment plan will be necessary. Such treatment can be very effectively directed by an otolaryngologist - head and neck surgeon like Dr Murali Mahadevan.

In summary, salivary gland diseases are due to many different causes. These diseases are treated both medically and surgically. Such treatment is readily managed by an otolaryngologist - head and neck surgeon with experience in this area like Dr Murali Mahadevan.